



## Combating photoaging with percutaneous collagen induction

Desmond Fernandes, MB<sup>a,\*</sup>, Massimo Signorini, MD<sup>b</sup>

<sup>a</sup>*The Renaissance Surgical Clinic and Department of Plastic Reconstructive Surgery, University of Cape Town, Cape Town 8001, South Africa*

<sup>b</sup>*Studio Medico Skin House, Istituto Dermatologico Europeo and University of Milan, Milan, Italy*

**Abstract** Medical clinicians are used to being consulted by patients who want to restore their youthful appearance. Although structural changes to the face and body may be achieved with surgery, for example, face lifts, the impression of youth also relies heavily on young-looking skin. It is desirable to have thicker and tighter skin to properly fulfill the desire for youth. Percutaneous collagen induction offers an antiaging effect to improve the appearance of old skin. It allows us to improve our patients' skin from the inside outward as well as from the surface. Experience has shown that percutaneous collagen induction works optimally when combined with a scientific skin care program to restore a youthful appearance. In addition, the same technique has proven to be very effective in minimizing acne scars and burn scars by removing scar collagen and replacing it with normal collagen. Consequently, scar contractures and depressed scars are improved. With the introduction of percutaneous collagen induction therapy in 1997, a simple and fast method was developed with regard to safely treating wrinkles and scars and producing lasting smoothness. As opposed to ablative laser treatments, the epidermis remains intact and is not damaged. For this reason, the operation can be safely repeated if needed, and it can be also applicable to regions where laser treatments or deep peelings cannot be done. © 2008 Elsevier Inc. All rights reserved.

Today, many patients come searching for a fairly rapid solution to their photoaged skin and want to look 10 years younger. This quest for younger-looking skin has spawned many different topical techniques, for example, carbon dioxide (CO<sub>2</sub>) laser resurfacing and deep peelings, which all share the same principle of damaging the skin to cause fibrosis. These treatments injure the skin and subsequently cause fibrosis of the papillary dermis. They tighten the skin or lighten scars because generally, they destroy the epidermis, which is replaced by an epidermis that no longer has dermal papillae and is thinner than the original tissue.

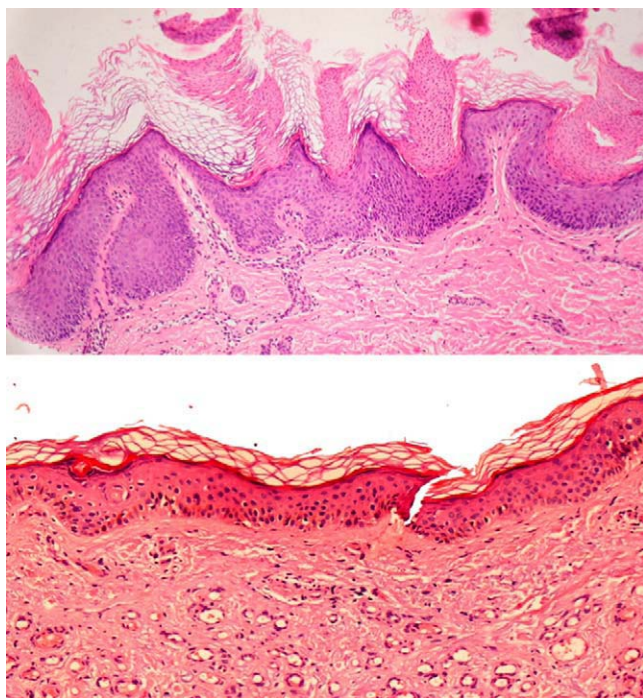
The destruction of the epidermis leads to severe changes in the dermis and consequently initiates an inflammatory response that propels the fibroblasts to produce scar collagen in parallel orientation rather than in the normal lattice network of normal skin. The skin becomes more sensitive to photodamage and may also develop dyschromias. Newer treatments have tried to preserve the epidermis completely (eg, radiofrequency tissue heating) or partially (eg, fractionated laser ablation), which cause necrosis of cells in the dermis. The necrosis is the stimulus for fibrosis. The fibrosis then causes tightening of the skin. Historically, skin peels were the first to rejuvenate skin but were followed by other destructive techniques such as CO<sub>2</sub> laser resurfacing. The principle is to destroy the epidermis either partially or almost completely to damage the fibroblasts and dermal structures

\* Corresponding author. Tel.: +27214244868; fax: +27214243997.  
E-mail address: [des@drdes.co.za](mailto:des@drdes.co.za) (D. Fernandes).  
URL: <http://www.drdes.co.za> (D. Fernandes).

sufficiently to stimulate an inflammatory response proportional to the damage, ultimately causing scarring and contraction of the collagen with skin tightening. The epidermis is the obstacle that has to be sacrificed to achieve the desired result. The epidermis is a self-renewing organ that rapidly grows over the damaged area. Deep treatments such as this stimulate myofibroblast activity that results in scarring rather than new, naturally oriented collagen formation. The sad fact is that several years after the treatment, the scar collagen will be resorbed—as all scar collagen is—and then fine wrinkles start to show up because of the thin epidermis with no dermal papillae.

Why destroy the epidermis to make the skin smoother? The epidermis is a most complex, highly specialized organ, and although it is only 0.2 mm thick, it is our only protection from the environment. We should never damage the epidermis unless the risk of leaving the epidermis intact is greater than removing it. Wrinkles are not a good excuse to destroy this wonderfully complex interface that we have with the world. Whatever we do, we should try and ensure that the basic normal architecture of the skin is not altered. To rejuvenate facial skin and really look young, we need a perfect epidermis with natural dermal papillae, good hydration, normal color, and normal resilience. In true rejuvenation, we also need to treat other areas of the body, so we need a technique that allows us to treat any area of skin safely.

The key to this is the induction of new collagen and elastin synthesis by the fibroblasts. Why is this so important? With the aging process, these structural proteins that give the



**Fig. 1** Top, Skin biopsy of 12-year-old patient. Compact collagen, thick epidermis, and deep dermal papillae. Bottom, Skin biopsy of 77-year-old patient. Elastotic, friable and fragmented collagen, thinned epidermis, and flattened papillae.

skin most of its physical properties are progressively destroyed, while fewer and fewer new ones are formed. Skin becomes lax, and gravitational folds and superficial fine lines appear. Indeed, whereas collagen and elastin synthesis is high in infancy, it tends to plateau in young adults. From then on, it constantly decreases with age. When the balance between protein synthesis and destruction becomes negative, the process of skin aging begins to appear (Fig. 1).

In adults, there is only one situation in which we witness a very significant physiologic increase in collagen and elastin formation, that is, after the production of a wound. Indeed, structural protein synthesis on behalf of the fibroblasts is key to wound healing, and ultimately, to survival, after injury. Therefore, this is a process we can rely on. The question is, can we afford to make a wound in a given area to increase collagen and elastin synthesis to reach an aesthetic improvement? How can we be sure not to produce an unsightly scar?

This chapter will be devoted to percutaneous collagen induction (PCI), which can be done to the face and any area on the body to achieve normal collagen induction without visible scarring. Although the technique may seem new, we actually have centuries of experience—tattooing—but in this case, without any pigment.

## Principles of the needling technique

Orentreich and Orentreich<sup>1</sup> described “subcision” as a way of building up collagen beneath retracted scars and wrinkles. Fernandes<sup>2</sup> independently and simultaneously used a similar technique to treat the upper lip by sticking a 15-gauge needle into the skin and then tunneling under the wrinkles in various directions parallel to the skin surface. The lip wrinkles were improved in many cases, but the problem was that bleeding caused severe unacceptable bruising, which sometimes resulted in hard nodules. Camirand and Doucet<sup>3</sup> treated scars with a tattoo gun to “needle abrade” them, and although this can be used on extensive areas, it is laboriously slow, and the holes in the epidermis are too close and too shallow. These techniques work because the needles break old collagen strands that tether the bed of the scar in the most superficial layer of the dermis, promote removal of damaged collagen, and induce more collagen immediately under the epidermis. Ideally, we need to get effects in the reticular dermis to stimulate the production of collagen and elastin fibers, but we must also avoid excessive bleeding under the skin. Based on these principles, a special tool was designed with needles ranging between 1 and 3 mm by Fernandes<sup>1</sup> to achieve PCI.<sup>4</sup>

## Environ Roll-Cit microneedling

Environ Roll-Cit (Cape Town, South Africa) microneedling is a revolutionary way to stimulate normal collagen

production for smoothening skin and treating fine wrinkles. This is a development of the Environ Roll-Cit medical needling, which has been featured on television in the United States. Medical needling uses 3-mm needles to penetrate deeper into the skin, and this does cause bruising and swelling. On the other hand, microneedling uses needles that only penetrate to a maximum of 1 mm, and this causes virtually no bruising and minimal swelling. With microneedling you can return to work the day after the treatment without any signs except some pink skin, as though you have been exposed to the sun. A series of 6 microneedling sessions should be done at intervals ranging from once a week to once a month—depending on the degree of improvement that is required. A major advantage of microneedling is that it can be done for lax skin or wrinkles of the face, upper lip lines, neck, decollete, arms, abdomen, buttocks, and legs. It is also useful for shallow acne scars and stretch marks.

## Preparing the skin

Photoaged skin has to be converted into healthier, functionally younger skin before PCI. Photoaging is not only due to the actual UV damage of dermal tissues but is also the result of a chronic deficiency of vitamin A. The first step toward skin health is to topically address this deficiency as well as the other antioxidant vitamins C and E and carotenoids, which are normally lost on exposure to light.

## The rationale for using vitamins A and C

Vitamin A, as retinoic acid, is an essential vitamin (actually a hormone) for skin that expresses its influence on about 400 to 1000 genes of skin cells. In general, vitamin A controls proliferation and differentiation of all the major cells of the epidermis and dermis. It is essential for rapid healing of the skin and also has been shown to facilitate collagen and glycosaminoglycans production by fibroblasts. It may control the release of transforming growth factor (TGF)  $\beta_3$  in preference to TGF- $\beta_1$  and - $\beta_2$  because in general retinoic acid seems to favor the development of a lattice-patterned collagen network rather than the parallel deposition of scar collagen.

Retinyl esters are the main form of vitamin A in the skin, and only tiny fractions of vitamin A are found as retinoic acid. Fortunately, retinyl esters are easily and rapidly converted into retinoic acid at physiologic doses. Retinyl esters do not irritate skin cells, whereas retinoic acid and retinol are cellular irritants and are less well tolerated. For that reason, we have chosen to use products with high levels of retinyl esters. One cannot understate the value of vitamin A in a rejuvenation program for skin. Vitamin A is utterly essential for the normal physiology of skin and for collagen preservation, but it is destroyed by exposure to light. Adequate nourishment of the skin with vitamin A (not necessarily as retinoic acid but rather

as retinyl esters, retinol, or retinaldehyde) will ensure that the metabolic processes for collagen production will be maximized, and the skin will heal as rapidly as possible.

Vitamin C is similarly important for collagen formation and is destroyed by exposure to blue light. These vitamins need to be replaced everyday so that the natural protection and repair of DNA can be maintained. As a result, the skin will take on a more youthful appearance. The addition of palmitoyl pentapeptide and/or other similar peptides will also ensure that better collagen will be formed. These chemicals, however, cannot achieve really youthful skin because the collagen immediately below the epidermis has been destroyed by years of sun exposure, and we need to stimulate the production of collagen in this area by a more targeted technique. Vitamin C is also essential for the production of normal collagen. The demand for vitamin C increases when more collagen is produced, for example, immediately after an operation. In this particular regard, needling focuses on creating more collagen, and so, it is mandatory to supply increased levels of vitamin C in the diet and topically. Ascorbic acid is not well absorbed into the skin and is also irritant to skin. On the other hand, ascorbyl tetraisopalmitate has been shown to be the most efficient form of vitamin C. It easily penetrates the skin and is also incorporated into skin cells, whereas ascorbic acid enters the cells with difficulty. Once the ascorbyl tetraisopalmitate is inside the cell, it is de-esterified and becomes bioavailable as ascorbic acid.

## Technique of PCI

The object of the procedure is to produce thousands of needle microlesions through the epidermis into the papillary dermis. These tiny wounds to the papillary dermis initiate the normal process of wound healing, which concludes in the synthesis collagen Types III and I. This happens in pre- and postmenopause females and in men. With the conversion of collagen Type III into collagen Type I, a tightening of the collagen lattice occurs naturally. This tightens lax skin and smoothenes out scars and wrinkles.

Once the skin has been prepared with topical vitamins A and C and antioxidants for at least 3 weeks, but preferably for 3 months, one can go ahead with PCI. If the stratum corneum is thickened and rough, a series of mild trichloroacetic acid peels (2.5% to 5% trichloroacetic acid in a special gel formulation) will prepare the skin surface for needling and maximize the result.

Under topical, local, or general anesthesia, the skin is closely punctured with the special medical needling tool,<sup>1</sup> consisting of a rolling barrel with needles at regular intervals. It comes in a sterile plastic container and is mounted on a handle at the time of use. Two different needle lengths are available, that is, 1 and 3 mm. By rolling backward and forward with some pressure in various directions, one can achieve an even distribution of the holes.



The needles penetrate through the epidermis (Fig. 2) but do not destroy it, and because the epidermis is only punctured, it will heal rapidly. The skin bleeds for a short while, but that soon stops. Of course, the skin develops multiple microbruises in the dermis, and these will actually initiate the complex cascade of growth factors that eventually results in collagen production. It is essential to use wet gauze swabs to soak up any ooze of serum when 3-mm needles have been used. Once the serous ooze has stopped, the skin is washed thoroughly and then covered with a special vitamin A, C, and E oil (do not use ascorbic acid!). If 3-mm needling has been done, the patient should be warned that he/she will look terribly red and bruised and become quite swollen (Fig. 3). The patient is encouraged to shower within a few hours of the procedure when back home.

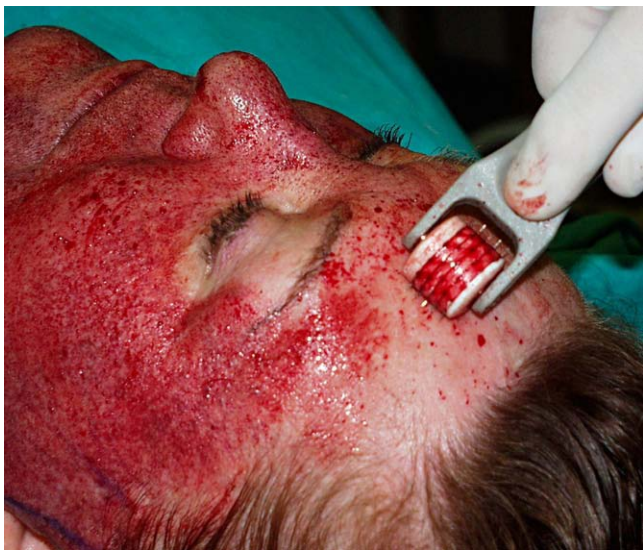If the skin has been needled with the 1-mm roller, the bleeding under the skin is microscopic, and one does not get a serous ooze postoperatively. If 1-mm needling has been done, the patient will only experience a flushed appearance of the skin and will not develop bruises or swelling (Fig. 4).

### Why PCI works

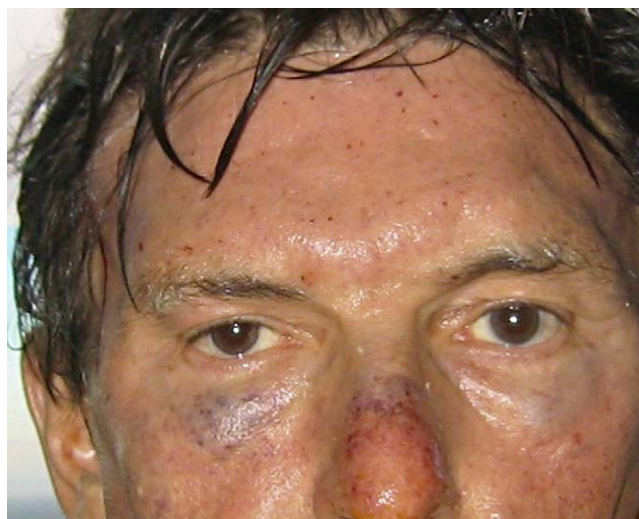
Percutaneous collagen induction results from the natural response to wounding the skin, although the wound is minute. A single needle prick through the skin would cause an invisible response. A completely different picture emerges when thousands or tens of thousands of fine pricks are placed close to each other.

### Normal stimulation of collagen production

There are 3 phases in the body's wound healing process, which follow each other in a predictable fashion.



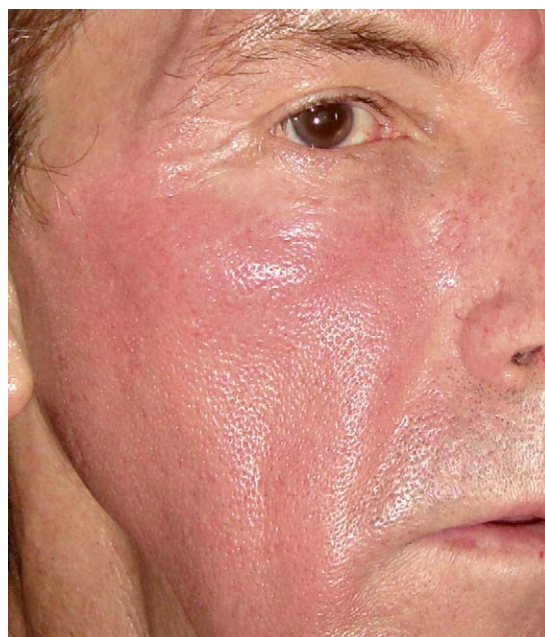**Fig. 2** The Roll-Cit 3-mm device for deep facial needling.



**Fig. 3** View of the skin immediately after washing after 3-mm Roll-Cit needling.

The first phase is the injury phase, which is characterized by trauma, bleeding (even slight), the release of platelets, and the ingress of neutrophils associated with inflammation. These cells release growth factors such as TGF- $\alpha$ , TGF- $\beta$ , platelet-derived growth factor, connective tissue-activating protein III, and connective tissue growth factor. These growth factors alter the activity of keratinocytes and fibroblasts.

In the second phase of wound healing, neutrophils are replaced by monocytes when tissue formation and proliferation cause epithelialization, angiogenesis, and collagen production. At this time, fibroblasts produce collagen III, elastin, glycosaminoglycans, and proteoglycans. At the same time, fibroblast growth factor, platelet-derived growth factor,



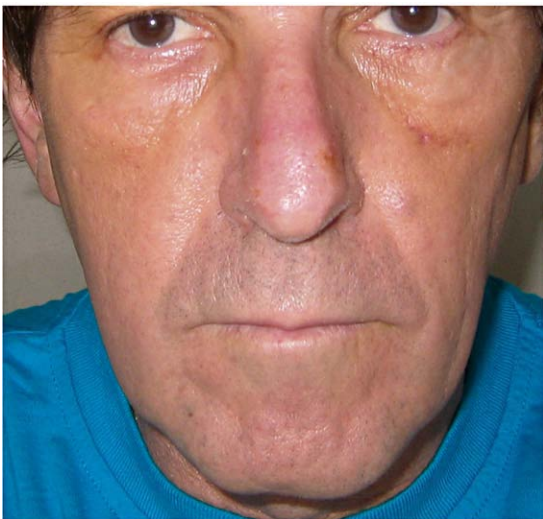**Fig. 4** View of the skin immediately after washing after 1-mm Roll-Cit needling.

TGF- $\alpha$ , and TGF- $\beta$  are secreted by the monocytes. Fibroblasts secrete insulinlike growth factor.

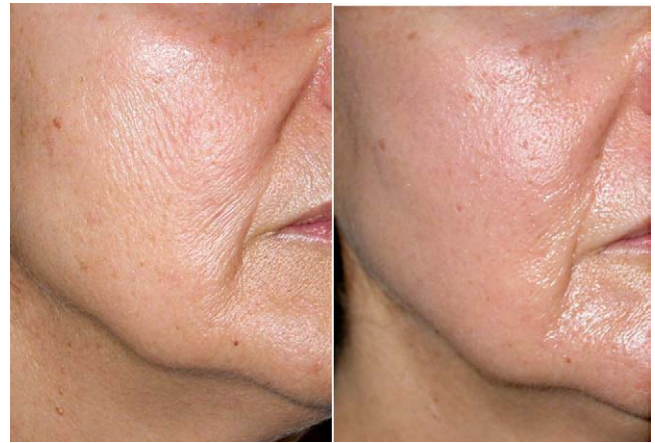In the third and last phase of the process, the wounds undergo maturation over the ensuing months. Collagenases and matrix proteinases are involved in the gradual conversion of collagen III into collagen I, which remains in the area for 5 to 7 years. The complete wound healing process is an overlap of these individual phases.<sup>5</sup>

When doing the 3-mm Roll-Cit needling, the needles penetrate about 1.5 to 2 mm into the dermis and automatically initiate a complex chemical cascade. Platelets instigate the release of various factors that set up a chain reaction with the eventual production of numerous growth factors. Fibroblasts migrate into the area, and this surge of activity inevitably leads to the production of more collagen and more elastin. Keratinocytes migrate rapidly across the minute epidermal defect and then proliferate, so the epidermis becomes thicker. Because this needling is deeper, it causes more trauma, and that means that swelling automatically follows.

If the 1-mm Roll-Cit device is used for microneedling, the bleeding is microscopic and entirely within the papillary and upper reticular dermis because the needles only penetrate about 0.75 mm at most. Because the epidermis is, on average, 0.2 mm, one can be certain that the injury will be limited to the upper layers of the dermis. This excites a smaller inflammatory response, yet the cascade of growth factors still gets initiated by the release of platelets through the puncturing of small vessels by microneedling. The possibility exists that with microneedling, one gets a purer stimulus for collagen synthesis without the heavy inflammatory reaction because subdermal fat is certainly not damaged at the same time. It is believed that because the epidermis is intact, this might favor predominantly TGF- $\beta$



**Fig. 5** Five days after 3-mm needling, most of the swelling has gone, and there is some residual bruising. This is in strong contrast to 1-mm needling, where the only sign at 24 hours is flushed skin.



**Fig. 6** Improvement of fine wrinkles of the cheek at 2 months.

rather than TGF- $\beta$ 1 and - $\beta$ 2, which are associated with scar collagen deposition. Transforming growth factor- $\beta$ 3 is implicated in scarless healing and normal lattice weave collagen deposition. Percutaneous collagen induction seems to induce normal lattice weave collagen rather than scar collagen,<sup>1</sup> so theoretically, TGF- $\beta$ 3 may play an important part in this very early phase.

Within 5 days after injury, a fibronectin matrix is laid down along the axis in which fibroblasts are aligned and along which collagen will also be laid down. This collagen is laid down in the upper dermis just below the basal membrane separating the dermis from the epidermis. Collagen Type III is the dominant form of collagen in the early wound healing phase. Tissue remodeling continues for months after the injury. Collagen Type III is gradually replaced by Collagen I over a period of a year or more.

### Care of the skin after PCI

Immediately after a 3-mm needling, the skin looks bruised, but bleeding is minimal, and serum oozes for a time after the bleeding stops. The patient is encouraged to use topical vitamin A and vitamin C cream or oils to promote better healing and greater production of collagen. The addition of peptides such as palmitoyl pentapeptide could possibly ensure even better results.

The skin feels tight and might look uncomfortable, but it is not.

The next day, the skin looks less dramatic, and by day 4 to 5, the skin has returned to a moderate pink flush that can be concealed with makeup. Some residual bruising may still be present (Fig. 5). Iontophoresis and sonophoresis of vitamins A and C will maximize the induction of healthy collagen and can be done the day after 3-mm needling. Iontophoresis also tends to reduce the swelling of the skin. Low-frequency sonophoresis can be used to enhance penetration of palmitoyl pentapeptide or other peptides.

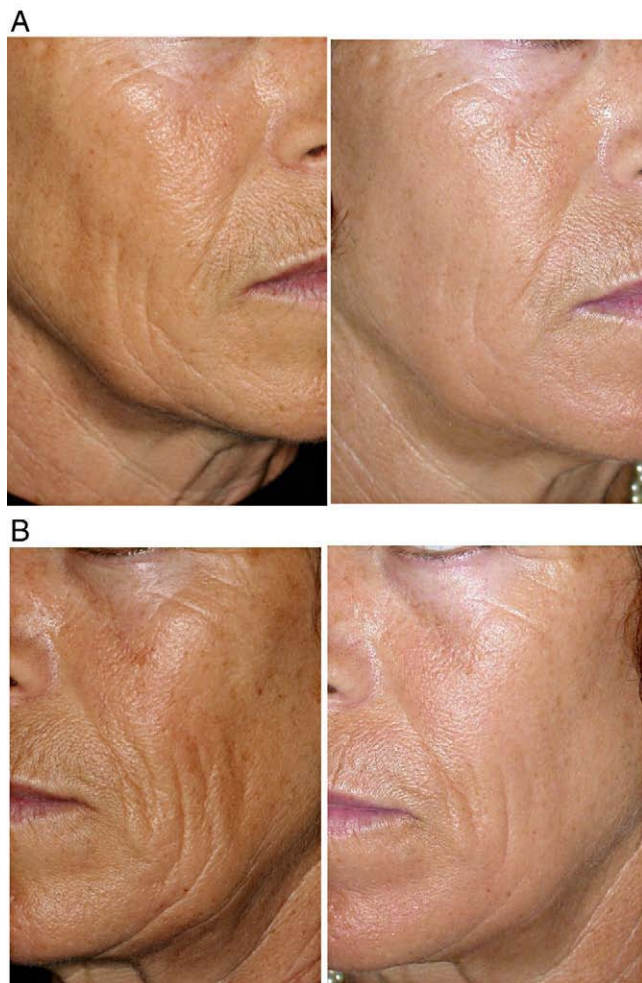

Our experience has shown that ascorbic acid is not safe to use on skin immediately after needling because it can cause superficial necrosis (peeling).

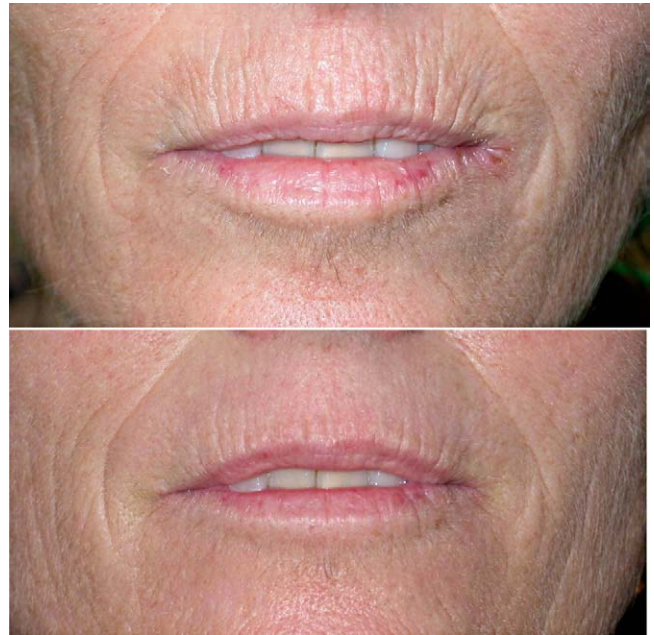If 1-mm needling has been done, the skin is treated as normal skin, and the patients should use their normal skin care regimen with high-dose vitamin A (preferably as retinyl esters) and vitamin C. Penetration can be enhanced by use of the Environ Cosmetic Roll-Cit the day after the medical treatment.

## Histology

Histology was done only on a few patients before and after needling. Von Giesen stains showed that 4 months after needling, there is a considerable increase in collagen deposition, and the collagen appears not to be laid down in parallel bundles but is in the normal lattice pattern. Increased amount of elastin has also been demonstrated.



**Fig. 7** A, Result at 4 months: note the skin tightening of the right cheek. B, Same patient at 4 months, left cheek.



**Fig. 8** Perioral rhytids treated with 2 needling procedures 6 months apart. Result after 1 year. Some lines have gone; others are still there but much more shallow.

The stratum corneum is normal, and the epidermis shows no signs of any abnormality and is of normal thickness with good rete peg formation. One could interpret the slides as showing that the rete pegs are better postoperatively than before operation.

## Indications for PCI using the 1-mm Roll-Cit

1. It can be used to restore skin tightness in the early stages of facial aging. This is a relatively minor procedure and can safely be recommended. Some patients who are worried about surgery may be satisfied with simple PCI. The arms, abdomen, thighs, and buttocks can also be treated. A course of 6 treatments is suggested.
2. Fine wrinkles are an excellent indication for needling of the skin.
3. As an alternative to dermabrasion for mild to moderate acne scarring. The skin becomes thicker, and the results are superior to dermabrasion.
4. To tighten skin after liposuction. Needling can be done immediately before or after liposuction and should be done again at intervals of 1 to 4 weeks for a minimum of 6 treatments.
5. Stretch marks.
6. Scars can be made less obvious by 1-mm needling, and if the scars are depigmented, one can achieve a better color match with the surrounding skin. If one is treating linear scars, a simple tattoo-artist gun can be used to needle abrade the scar as described by Camirand and Doucet.<sup>3</sup>

## Indications for PCI using the Environ 3-mm Roll-Cit

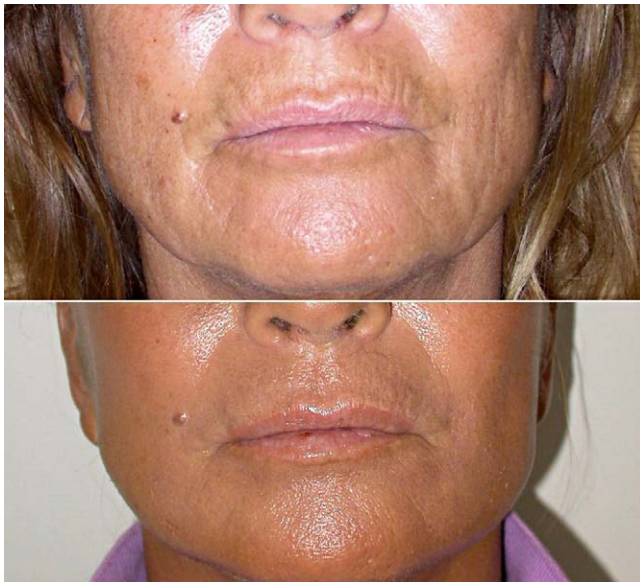1. Deep acne scars
2. Burn scars
3. Severe stretch marks

## Patient satisfaction

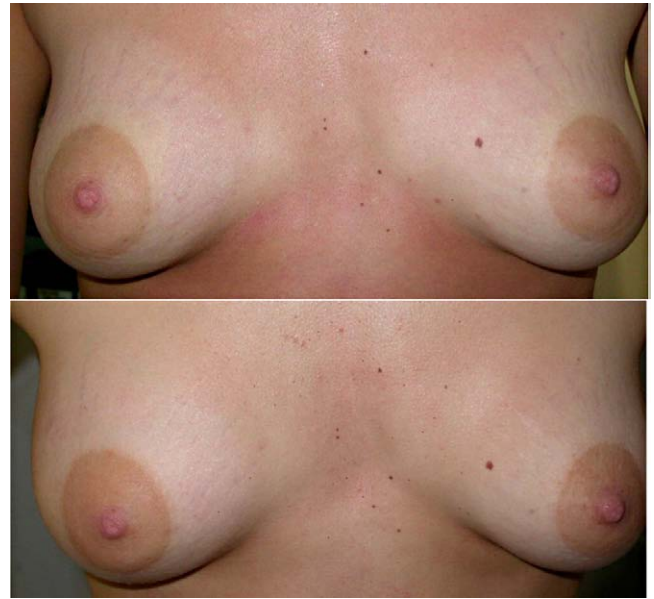
Patient satisfaction was evaluated with the visual analogue scale from 0 to 10 (0 = absolutely dissatisfied, 10 = completely satisfied). The mean score of the operation's result in the wrinkle group was 8.5 (minimum, 7; maximum, 10), and in the scar treatment group, 7.5 (minimum, 7; maximum, 8). Typical results are illustrated in Figs. 6-10.

## Advantages of PCI

1. Percutaneous collagen induction does not damage the skin.
2. Any part of the body may be treated.
3. Skin becomes thicker.
4. The healing phase is short.
5. It is not as expensive as laser resurfacing.
6. The skin does not become sun sensitive.
7. It can be done on people who have had laser resurfacing or those with very thin skin.
8. Telangiectasias may disappear.



**Fig. 9** A good combination: rhytidectomy (face lift) with perioral needling to improve the skin texture and the lines around the mouth. Result at 6 months.



**Fig. 10** Significant reduction of periareolar stretch marks at 5 months.

9. It does not require specific plastic-surgical or dermatological skills but can be done by trained medical staff.
10. The technique is easy to master with the new tool that has been specifically designed for the procedure.
11. It can even be done with topical anesthesia.
12. Hyperpigmentation has not yet been described in well more than a thousand cases of needling. This should not be a surprise because tattoos are virtually never hyperpigmented even in darker-skinned people. If a problem does arise with a tattoo, it is due to the pigment used rather than the technique, even under the most primitive unhygienic conditions. The authors have never seen hyper- or hypopigmentation after needling in patients with darker skin, for example, African, Indian, Malaysian, Chinese, and Mediterranean skin.

## Disadvantages of PCI

1. Exposure to blood. With 1-mm needling, the external bleeding is minimal, but with 3-mm needling, there is relatively much more bleeding.
2. Although we cannot achieve as intense a deposition of collagen as in CO<sub>2</sub> laser resurfacing, we can repeat the treatment and get even better results that will last just as long, if not longer.
3. Overaggressive needling may cause scarring especially when using a tattoo gun.
4. There is a need for thorough anesthesia of the skin when doing 3-mm needling.



5. It takes a longer time to see the result than with laser resurfacing.
6. There is unsightly swelling and bruising for first 4 days when 3-mm needling has been done.

## Discussion

There is a general consent in the medical literature that the most effective treatment of wrinkles is by use of the CO<sub>2</sub> laser. Although the skin may be smoothest after this treatment, however, it is also thin, usually much lighter than before, and almost always sun sensitive. In the case of laser resurfacing, the smoothening is due to the deposition of dense scar collagen in the papillary dermis. Histologic examination will show that the epidermis is thinner than before and that the rete pegs are generally flattened. This inevitably leads to poor nourishment of the epidermis. The high incidence of complications has made CO<sub>2</sub> laser resurfacing less popular than it was several years ago. Newer and less aggressive laser procedures using lower energies or fractionated destruction have preserved the epidermis to a much larger extent, but at the same time, the production of collagen has also been reduced.

Lasers, in general, destroy the epidermis to instigate the natural posttraumatic inflammatory cascade. The question, however, should be, "Why destroy the epidermis to achieve smooth skin?" The epidermis is a complex, highly specialized organ that is our primary protective layer from the environment, although it is only 0.2 mm thick. We should never injure the epidermis for cosmetic reasons. We should only destroy the epidermis for medical reasons. Wrinkles are not a good excuse to compromise this wonderfully complicated interface with the environment.

To attain a smoother, healthy, younger-looking skin with even coloring, we need to promote the proliferation and differentiation of the skin cells maximally. We need a healthy blood supply to the skin, which should be naturally well hydrated.

The first stride to healthier skin is to restore the natural levels of photosensitive vitamins (eg, vitamins A and B12) and other antioxidants, such as vitamins C and E as well as

carotenoids, which are normally depleted after exposure of the skin to light each day. This is most conveniently done by using scientifically formulated creams with adequate doses of these essential ingredients to address the deficiency that results from normal daily life. Vitamins working on their own, however, cannot build up enough collagen and elastin.

As an alternative to laser treatments, we have used skin needling, which protects the epidermis and stimulates natural collagen synthesis. Orentreich and Orentreich<sup>1</sup> and Fernandes<sup>2</sup> independently described subcision or dermal needling by pricking the skin with a needle to scarify the dermis and build up connective tissue under scars and wrinkles. This technique, however, could not be used on large body surface areas. Camirand and Doucet<sup>3</sup> used a tattoo pistol to treat scars with "needle abrasion." Although this technique can be used on larger areas, it is slow and laborious. The fundamental similarity of these different techniques is that the needles break old collagen structures that connect the scar with the upper dermis. The trauma induces the inflammatory cascade, scar collagen is broken down, and new collagen is replaced once again under the epidermis. Based on these principles, Fernandes<sup>4</sup> developed a new technology, PCI. This is a simple technique, and with the right tool, it becomes easy and fast to puncture any skin thoroughly. Although one treatment may not give the smoothening seen with laser resurfacing, the epidermis is virtually normal, and if the result is not sufficient, it can be repeated. The technique can be used on areas that are not suitable for peeling or laser resurfacing.

## References

1. Orentreich DS, Orentreich N. Subcutaneous incisionless (subcision) surgery for the correction of depressed scars and wrinkles. *Dermatol Surg* 1995;21:6543-9.
2. Fernandes D. Upper lip line treatment. Delivered paper, ISAPS conference, Taipei; 1996.
3. Camirand A, Doucet J. Needle dermabrasion. *Aesthetic Plast Surg* 1997; 21:48-51.
4. Fernandes D. Minimally invasive percutaneous collagen induction. *Oral and Maxillofacial Surgery Clinics of North America* 2006;17:51-63.
5. Cohen KI, Diegelmann RF, Lindbland WJ. Wound healing: biochemical and clinical aspects. Philadelphia: W.B. Saunders Co; 1992.